

## Small Stiff Swelling over Flexor Aspect of the Finger

Sonal Saran<sup>1\*</sup>, Manvendra Gaur<sup>2</sup>

<sup>1</sup>Department of Radiology, AIIMS, Rishikesh, Uttarakhand, India, <sup>2</sup>Department of Orthopedics, Subharti Medical College, Meerut, Uttar Pradesh, India

### SECTION 1 – QUIZ

#### CASE

A 30-year-old male patient presented to the orthopedic outpatient clinic with the complaint of a small painful, stiff mass over the flexor aspect of the left ring finger for three months. There was no history of antecedent trauma and no

apparent restriction of finger movements. The swelling was small, firm, and tender. The temperature of the overlying skin was normal. The patient was sent to the Radiology Department for a high-frequency ultrasound examination of the finger to determine the nature of the swelling [Figure 1 and Video 1]. What is your interpretation?

#### Declaration of patient consent

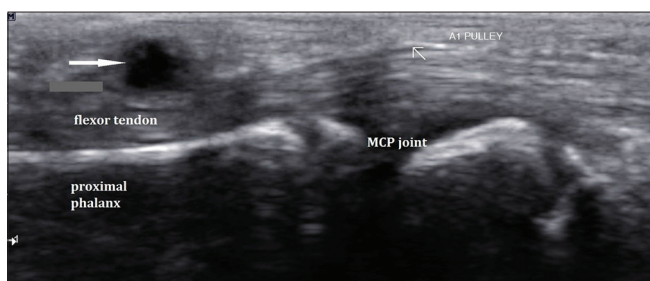
The authors certify that they have obtained all appropriate patient consent forms. In the form, the patient has given his consent for his images and other clinical information to be reported in the journal. The patient understands that his name and initials will not be published, and due efforts will be made to conceal the identity, but anonymity cannot be guaranteed.

#### Financial support and sponsorship

Nil.

#### Conflicts of interest

There are no conflicts of interest.



**Figure 1:** Ultrasound image over palmar aspect of the left ring finger in the longitudinal plane

Received: 07-12-2020 Revised: 19-12-2020 Accepted: 04-01-2021 Available Online: 05-04-2021

Video Available on: [www.jmuonline.org](http://www.jmuonline.org)

Access this article online

Quick Response Code:



Website:  
[www.jmuonline.org](http://www.jmuonline.org)

DOI:  
10.4103/JMU.JMU\_175\_20

**Address for correspondence:** Dr. Sonal Saran,

Department of Radiology, Subharti Medical College, Meerut,  
Uttar Pradesh, India.

E-mail: [sonalsaranmalik@gmail.com](mailto:sonalsaranmalik@gmail.com)

This is an open access journal, and articles are distributed under the terms of the Creative Commons Attribution-NonCommercial-ShareAlike 4.0 License, which allows others to remix, tweak, and build upon the work non-commercially, as long as appropriate credit is given and the new creations are licensed under the identical terms.

**For reprints contact:** [WKHLRPMedknow\\_reprints@wolterskluwer.com](mailto:WKHLRPMedknow_reprints@wolterskluwer.com)

**How to cite this article:** Saran S, Gaur M. Small stiff swelling over flexor aspect of the finger. J Med Ultrasound 2021;29:307.